

CASE STUDY

CT-SCANNING OF A GERMAN HUNTING TERRIER WITH OTITIS EXTERNA/OTITIS MEDIA, PERFORMED AT ØSTERGAARDS DYREHOSPITAL, TRANBJERG

INTRODUCTION

Otitis media is a common perpetuating factor in otitis externa, in one study observed in 25/100 cases. (1)

CASE

This is a case of a 2 year-old German Hunting Terrier with recurring otitis externa. Prior to referral, a variety of medical and topical treatments had been attempted without success, resulting in a chronic proliferative otitis externa. Upon physical examination, the left ear canal showed so much tissue proliferation, that inspection of the tympanic membrane was impossible.

Blood work including a hematological examination and a biochemistry panel showed neutrophilia and monocytosis, but otherwise there were no abnormal findings. Due to the chronic long-term nature of this particular case, a CT scan was performed prior to treatments of the ear canal. The CT scan showed significant tissue proliferation in the middle ear, presumably due to rupture of the tympanic membrane and invasion of bacteria, fungi and tissue originating from the external ear canal. (fig. 1, 2)

CONCLUSION

Being able to CT scan this particular patient enabled us to correctly diagnose middle ear involvement in this case as well as assess tympanic membrane status, which was crucial to treatment plan and patient well-being.

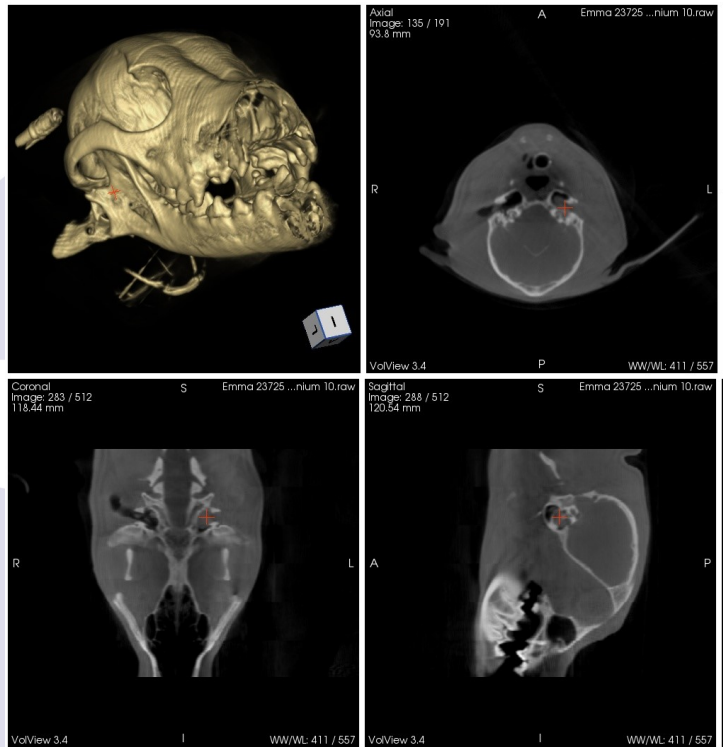


Fig. 1

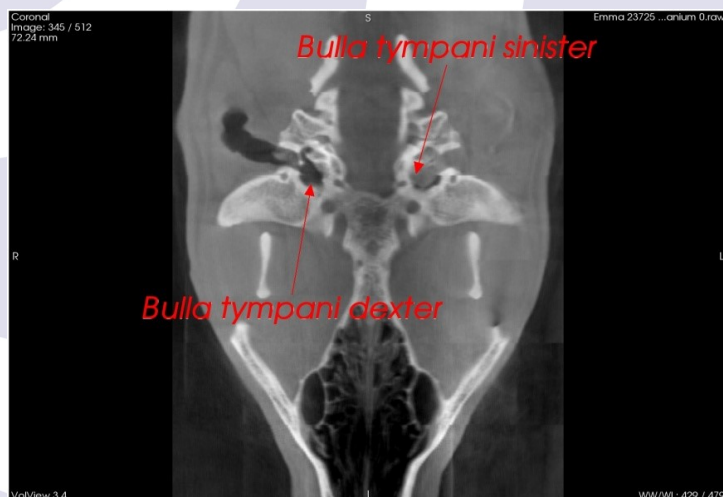


Fig.2

1) Saridomichelakis MN, Farmaki R, Leontides LS, Koutinas AF, Aetiology of canine otitis externa: A retrospective study of 100 cases, Vet Dermatol. 2007 Oct; 18(5): 341-7

DVM Ulrik Oudrup Bech